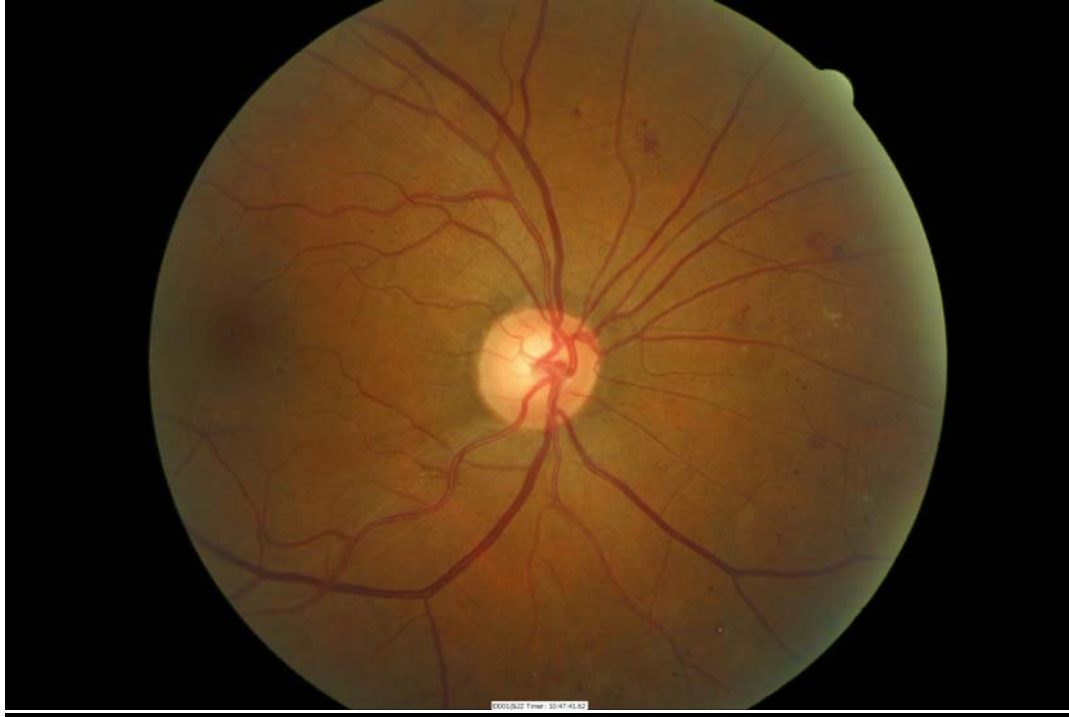
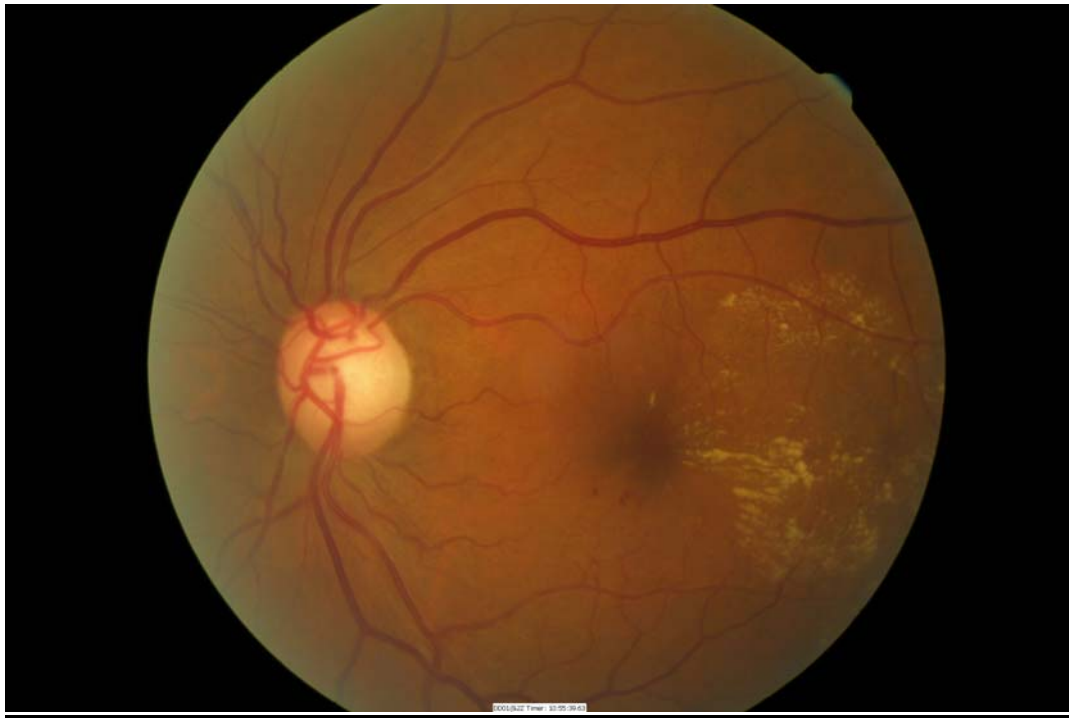
STAGES OF DIABETIC RETINOPATHY (EXAMPLE IMAGES)

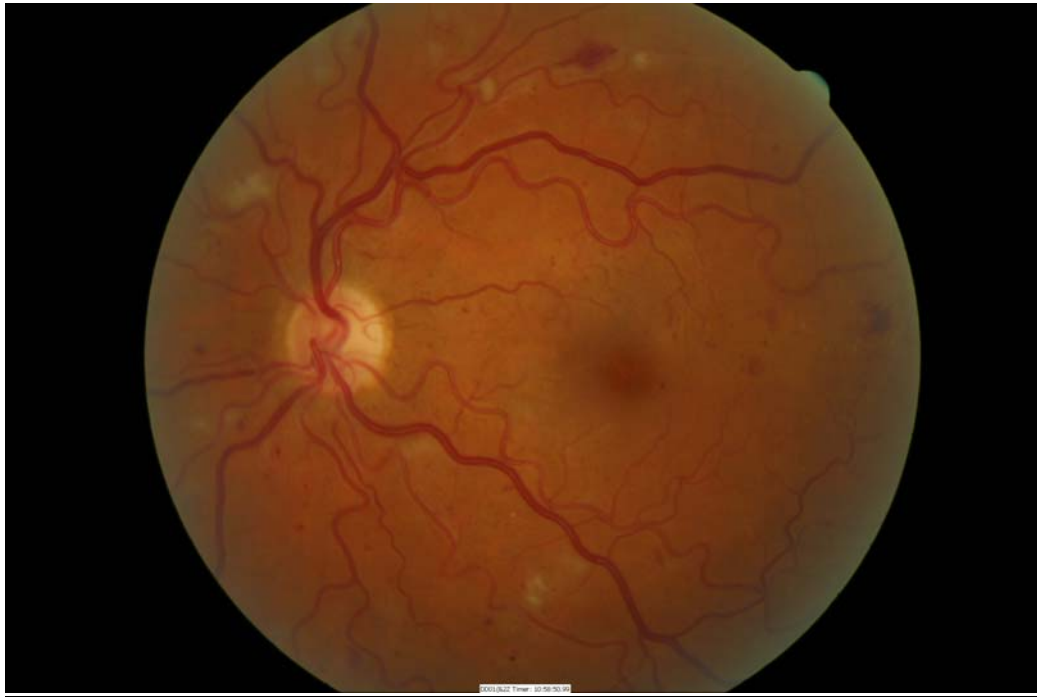BACKGROUND (R0)



MACULOPATHY (M1)

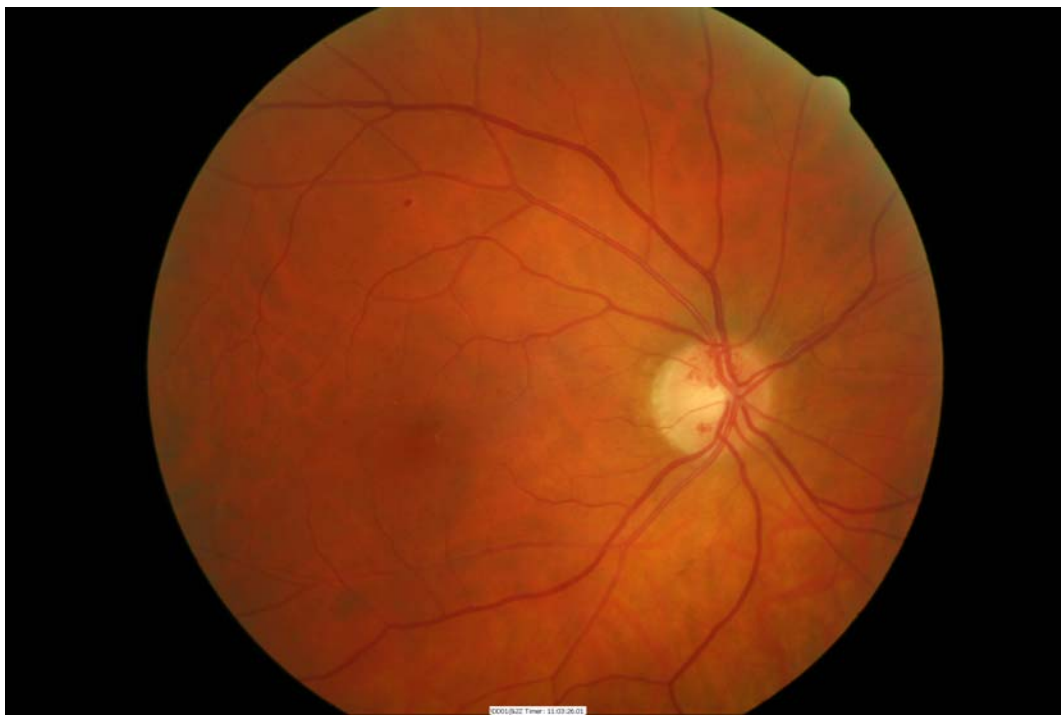

PRE-PROLIFERATIVE (R2)

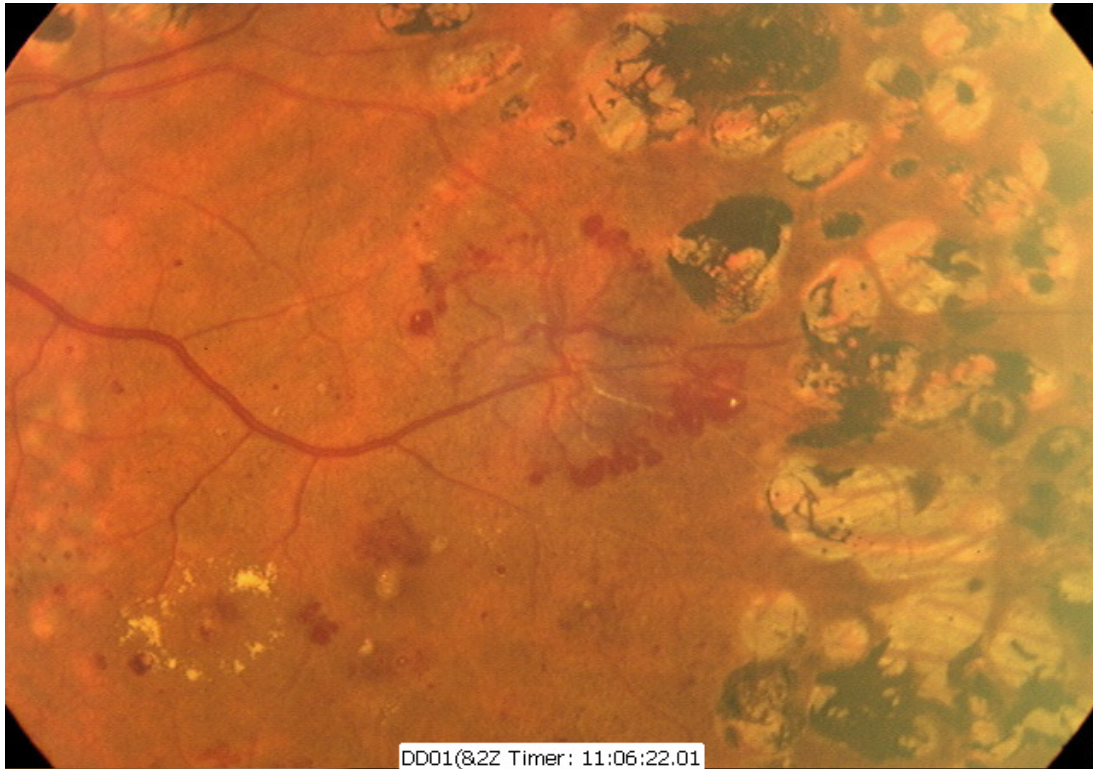


PROLIFERATIVE (R3)

DISC NEW VESSELS (DNV)

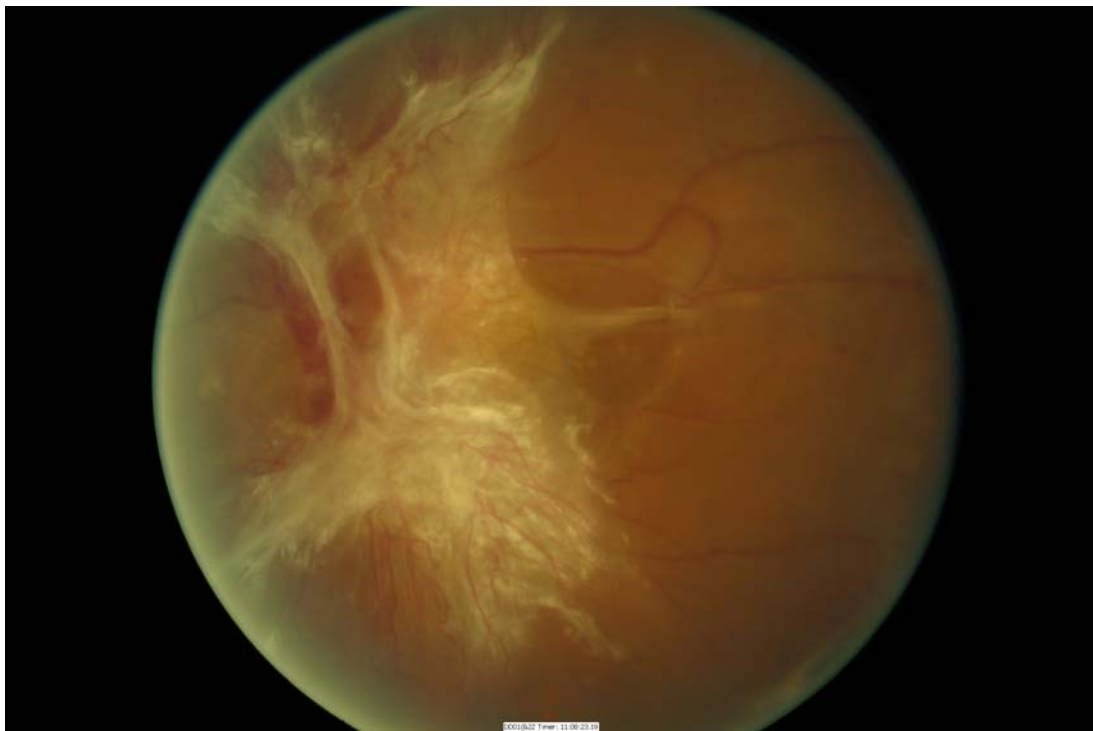


NEW VESSELS ELSEWHERE (NVE)



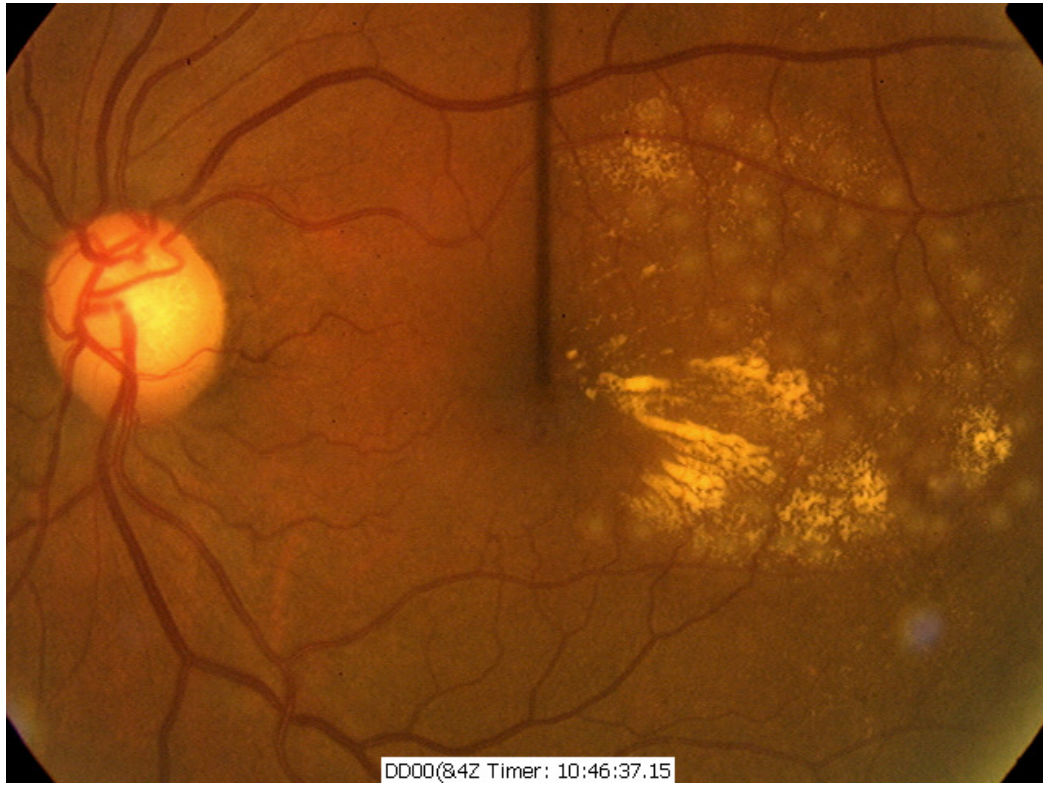
(Note also old pan retinal laser scars)

END STAGE DIABETIC RETINOPATHY



(Note gliosis of DNV with traction of the retina in the superior temporal region)

FOCAL LASER TREATMENT



PAN RETINAL PHOTOCOAGULATION

